

Comparative Evaluation of the Gastroprotective Effect of L-Carnitine and Omeprazole on Ethanol-Induced Gastric Ulcer in Male Albino Wister Rats

Nermin M. Madi* and Anaam S. Abd al-Barr**

Departments of Physiology* and Clinical Pathology**

Faculty of Medicine, Tanta University

Abstract

Aim: The present work aimed to compare between the gastroprotective efficacy of L-carnitine and omeprazole in ethanol-induced gastric ulcer in male albino Wister rats. **Methods:** This study was carried out on 40 male albino Wister rats were divided into four equal groups: Normal group: Received distilled water, ulcer-control group: Administered with a single dose of 1ml absolute ethanol for gastric ulcer induction, omeprazole-group: Received omeprazole (20mg/kg subcutaneously daily), L-carnitine group: Received L-carnitine (50mg/kg) intragastrically. At the end of experiment, ulcer index and preventive index were assayed. Gastric homogenate was collected for determination of total antioxidant capacity (TAC), superoxide dismutase (SOD) and catalase (CAT) activities, nitric oxide (NO), acidic mucopolysaccharides, prostaglandin E2 (PGE2) and myeloperoxidase (MPO) activity. Gastric juice was collected for determination of titratable acidity, peptic activity and DNA fragmentation. **Results:** The ethanol-induced gastric damage significantly increased ulcer index, MPO activity, titratable acidity, peptic activity and DNA fragmentation of gastric juice, with significant decrease in TAC, SOD activity, NO, acidic mucopolysaccharides and PGE2 in gastric mucosa, with no effect on CAT activity compared to normal group. Pretreatment with either omeprazole or L-carnitine significantly decreased ulcer index, gastric MPO activity, titratable acidity, peptic activity and DNA fragmentation compared to ulcer-control group. Also, both omeprazole and L-carnitine significantly increased gastric TAC and SOD activity with insignificant effect on CAT compared to ulcer control group. But L-carnitine, not omeprazole, significantly increased NO, acidic mucopolysaccharides and PGE2 compared to ulcer control. **Conclusions:** We conclude that L-carnitine is more effective in healing the gastric ulcer than omeprazole. Further broad spectrum studies as well as clinical trials should be conducted before the use of L-carnitine as routine medicine.

Received: June 21st 2014
Accepted: Sept 20, 2014
Available online: Dec 10, 2014

Keywords

- Acidic mucopolysaccharides
- L-carnitine
- DNA fragmentation
- Omeprazole
- Superoxide dismutase

INTRODUCTION

Gastric ulcer is a common disease with multiple etiologies, defined as a discontinuity in the gastric mucosa (1). It usually results from imbalance between the gastric mucosal protective factors, i.e., the gastric mucosal barrier and the aggressive factors, to which the mucosa is exposed(2). Aggressive factors which promote gastric mucosal injury include gastric hydrochloride (HCl)(3), mucosal hypoperfusion,(4), free oxygen radicals(5), and ethanol(6), etc. The experimental model of ethanol-induced gastric mucosal damage in rats is widely used to assess the protective and healing activity of many drugs in ulcer studies(7), due to its ability to reduce endogenous NO level and blood flow in gastric mucosa, which leads to a serious hemorrhagic necrosis and consequently depletes gastric mucus constituents, elevated pepsin secretion, loss of H⁺ and histamine into the lumen(8). Not only alcohol causes direct gastric mucosal damage, its abuse is also associated with development of gastric diseases such as gastritis and even gastric cancer(9).

Proton pump inhibitors (PPIs) are widely used for a long time in the treatment of gastric ulcer diseases(10). Omeprazole, one of the PPIs, binds to the H⁺/K⁺-ATPase enzyme system (proton pump) of the parietal cell and suppress the secretion of hydrogen ions into the gastric lumen(11). This irreversibly inactivates the H⁺/K⁺-ATPase enzyme causing profound inhibition of acid secretion(12). Omeprazole is degraded at low pH and must be given in enteric-coated granules(13). Clinical studies have shown that PPIs reduce the risk of bleeding from a gastric

ulcer(14). The antisecretory effect of omeprazole results in an elevation of serum gastrin concentrations, which in humans appear to be related to the degree of acid suppression (15). However, previous studies in the rat in which massive doses of omeprazole have been used, have shown markedly elevated gastrin levels associated with Enterochromaffin-like cell hyperplasia and gastric carcinoid tumors, which have been found after long-term treatment(16).

Carnitine is a vitamin like substance that structurally similar to amino acids, it acts as a carrier for fatty acids across the inner mitochondrial membrane for subsequent beta-oxidation(17). Carnitine is obtained from diet, it can also be synthesized endogenously by skeletal muscle, heart, liver, kidney and brain from the amino acids lysine and methionine(18). Carnitines are essential cofactors of several enzymes necessary for the transformation of long-chain fatty acids(17), and act also as scavengers of oxygen free radicals in mammalian tissues(19). It is, therefore, possible that L-carnitine could scavenge free radicals and produce beneficial effects against gastric mucosal ulcer.

The aim of the present study to compare between the gastroprotective efficacy of L-carnitine and omeprazole in ethanol-induced gastric ulcer in male albino Wister rats.

MATERIALS AND METHODS

Animals:

Forty male albino Wister rats, weighing 200-250g, rats were housed in clean cages, five rats per each cage. They were housed at 28±2°C, under a 12light/dark cycle and free access to food and water. The rats were deprived of food for 24h

before experimentation, but were allowed free access to drinking water.

Drugs and chemicals:

Omeprazole (Losec) was provided by Astrazeneca Co., L-carnitine was obtained from Sigma chemical Co.

Experimental design:

The animals were randomly divided into four groups (10 animal per group):

Normal control group; Animals were received 1ml of distilled water orally by intragastric gavage every day for two weeks.

Ulcer control group; In which gastric ulcers were induced by intragastric administration of a single dose of 1ml of absolute ethanol to each rat(20).

L-carnitine group; In which animals received L-carnitine (50mg/kg) suspended in 1 ml of distilled water by intragastric gavage daily(21) for two weeks before the induction of gastric ulcer by ethanol.

Omeprazole group; In which animals were treated with omeprazole (20mg/kg) subcutaneously daily(22). Omeprazole was given for 2 weeks before the induction of the gastric ulcer by ethanol.

Pyloric ligation was carried out, immediately before ethanol administration and in normal control, according to the method described by Chandra et al.(23)

The animals were sacrificed, by cervical decapitation, 60 minutes after the administration of ethanol. The stomach of each animal was then removed, opened along the greater curvature, the gastric juice was collected.

Macroscopic evaluation of gastric mucosa:

Gastric mucosa was examined for mucosal necrotic lesions; the gastric ulceration was then expressed in the following terms:

(1) Lesion size (mm) was determined by measuring each lesion and its greatest diameter recorded in the case of petechial lesions. The grade of the lesions was scored as following: no lesion=0, 1-2mm=1, 3-4mm=2, 5-6mm=3 and >6mm=4(24).

(2) Ulcer index (U.I.)= the incidence of ulcer multiplied by the ulcer severity score in this group(25).

(3) Mean ulcer score (calculated by dividing the total number of ulcers in each group by the number of rats in that group(24).

(4) Preventive index (P.I.) of a drug was calculated as following(26)

$$P.I.= 100 \times \frac{U.I. \text{ of ulcer control group} - U.I. \text{ of treated group}}{U.I. \text{ of ulcer control group}}$$

Biochemical analysis of gastric mucosa:

Stomach tissues were cut into small pieces and homogenized. The homogenate of gastric tissue was used for assay of total antioxidant capacity (TAC) according to the method described by Koracevic et al.(27), the results were expressed as $\mu\text{M/g}$ tissue, superoxide dismutase (SOD) activity was assayed by the method described by Misra and Fridovich(28), results were expressed as Units (U) of SOD activity/g tissue, catalase (CAT) activity of gastric mucosa was assayed by the method of Aebi(29), results were expressed as k/g tissue, NO metabolites were determined according to the method of Miranda et al.(30) and results were expressed as $\mu\text{M/g}$ tissue, acidic mucopolysaccharides, as an indicator of the gastric

mucosal barrier, was determined according to the method of Yusuf et al.(31), results were expressed as $\mu\text{g/g}$ tissue, gastric prostaglandin E2 (PGE2) level according to the method described by Shimamoto et al. (32), results were expressed as pg/g tissue, and myeloperoxidase (MPO) activity was measured according to the method of Zhao et al.(33), and results were expressed as U/g tissue.

Analysis of the gastric juice:

The gastric contents were then collected. They were centrifuged at 3000 rpm for 20 min. The supernatant was subjected to analysis for titratable acidity according to Cylwik et al.(34), results were expressed as mEq/L, peptic activity of the gastric juice was determined according to the method described by Onasanwo et al.(35), results were expressed as μM tyrosin/ml, and determination of the DNA fragmentation in the gastric juice of luminal content, as an apoptotic marker, was measured colorimetrically according to the method described by Kurita-Ochiai et al.(36), results were expressed as mg/L.

Statistical analysis:

The data were expressed as the mean \pm standard deviation. Data from our study were analyzed using the unpaired student's t-test to assess significant difference between two groups. Statistical comparison between different groups was carried out by using one-way ANOVA. Significant results of analysis of variance were subjected to post hoc analysis (Tukey-Kramer multiple comparisons). P-values <0.05 were considered statistically significant. All the analyses were performed using Graph Pad Instat, 32 bit for win 95/NT (Version 3.05).

RESULTS

Our results were shown in table 1, 2, 3 & 4 and fig. 1, 2, 3, 4 & 5 as following:

Effect of omeprazole and L-carnitine on gastric ulcer index & preventive index:

Table 1 & figure 1 showed that administration of ethanol significantly increased the ulcer index as compared to the normal group. While, administration of either omeprazole or L-carnitine, 2 weeks prior to ethanol, significantly decreased the ulcer index ($P<0.05$) in the gastric wall compared to the ulcer control group. The preventive index was recorded 54.7% and 67.6% for omeprazole and L-carnitine treated groups respectively.

Effect of omeprazole and L-carnitine on gastric mucosal TAC, SOD and CAT levels:

Ethanol administration significantly reduced the gastric TAC levels by about 22.6% and also significantly decreased the gastric level of SOD activity by 63.1% compared to the normal group. But, the CAT activity was unchanged after ethanol administration (figure 2).

Pretreatment with either omeprazole or L-carnitine for 2 weeks prior to ethanol administration significantly increased the TAC in rat stomach by about 22% and 27.4% respectively compared to the animals given ethanol alone. Also, Either omeprazole or L-carnitine pretreatment significantly increased the SOD activity in gastric mucosa by about 174.2% and 219.8% respectively compared to ulcer control. With more observed significant increase in SOD activity due to L-carnitine administration by about 14.3% compared to omeprazole administration (figure 2).

Neither omeprazole nor L-carnitine administration prior to ethanol had any effect on the CAT activity in the gastric mucosa (figure 2).

Table (1): Effect of Omeprazole and L-carnitine pretreatment on ulcer index and preventive index in ethanol-induced gastric ulcer in male albino Wister rats:

| Groups | Ulcer index | Preventive index |
|---------------|--------------------------|------------------|
| Normal | 0.7±.48 | - |
| Ulcer control | 22.5±4.74 ^a | - |
| Omeprazole | 10.2±1.87 ^{a,b} | 54.7% |
| L-carnitine | 7.3±2.31 ^{a,b} | 67.6% |

Data are given as mean ± SD.

^aP < 0.05 vs normal group. ^bP < 0.05 vs ulcer control group. ^cP < 0.05 vs omeprazole group.

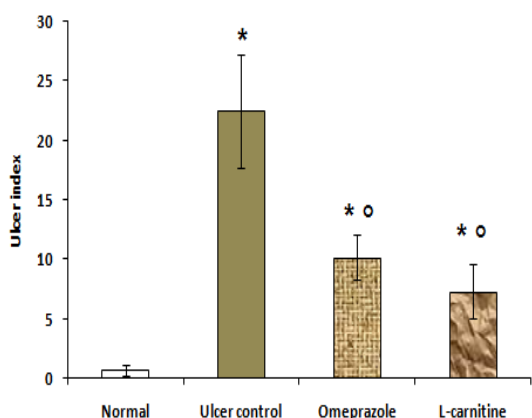


Figure (1): Effect of Omeprazole and L-carnitine pretreatment on ulcer index and preventive index in ethanol-induced gastric ulcer in male albino Wister rats: Data are given as mean ± SD. *P < 0.05 vs normal group. ^oP < 0.05 vs ulcer control group. [#]P < 0.05 vs omeprazole group.

Effect of omeprazole and L-carnitine on gastric mucosal NO content:

Table 2 showed that ethanol significantly reduced the gastric mucosal NO content as compared to the normal group. Rats pretreated with omeprazole showed insignificant change in NO content compared to the ulcer control group.

While, rats pretreated with L-carnitine showed significant increase in the gastric NO content compared to the ulcer control.

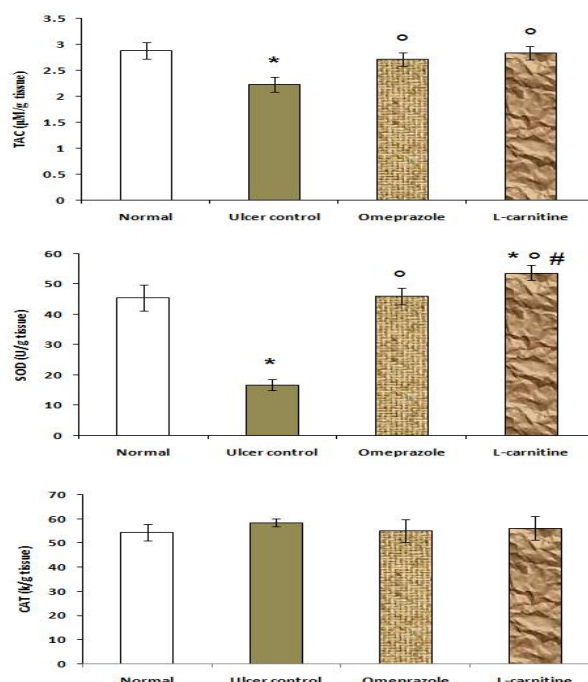


Figure (2): Effect of Omeprazole and L-carnitine pretreatment on TAC, SOD, CAT in ethanol-induced gastric ulcer in male albino Wister rats: Data are given as mean ± SD. *P < 0.05 vs normal group. ^oP < 0.05 vs ulcer control group. [#]P < 0.05 vs omeprazole group.

Table (2): Effect of Omeprazole and L-carnitine pretreatment on acidic mucopolysaccharides, NO, in ethanol-induced gastric ulcer in male albino Wister rats:

| Groups | NO (µM/g protein) | Acidic mucopolysaccharides (µg/g tissue) |
|---------------|--------------------------|--|
| Normal | 4.73±0.31 | 50.51±4.74 |
| Ulcer control | 3.67±0.28 ^a | 22.40±3.14 ^a |
| Omeprazole | 3.72±0.34 ^a | 23.26±3.04 ^a |
| L-carnitine | 4.94±0.17 ^{b,c} | 49.95±4.54 ^{b,c} |

Data are given as mean ± SD.

^aP < 0.05 vs normal group. ^bP < 0.05 vs ulcer control group. ^cP < 0.05 vs omeprazole group.

Effect of omeprazole and L-carnitine on gastric mucosal acidic mucopolysaccharides:

Ethanol administration significantly reduced the acidic mucopolysaccharides from (50.51± 4.74µg/g tissue) in the normal group to (22.40±3.14µg/g tissue) in the ulcer-control group. Pretreatment with omeprazole insignificantly altered the acidic mucopolysaccharides levels as compared to the ulcer control. However, pretreatment with L-carnitine significantly increased the acidic mucopolysaccharides levels to (49.95±4.54µg/g tissue) by about 123% increased compared to the ulcer control (Table 2).

Effect of omeprazole and L-carnitine on gastric mucosal PGE2 levels:

As shown in figure 3, ethanol administration significantly reduced the PGE2 level as compared to the normal group. While, omeprazole, treatment 2 weeks prior to ethanol administration, insignificantly changed PGE2 level compared to the ethanol-induced gastric ulcer group. But, L-carnitine treatment 2 weeks prior to the ethanol administration significantly increased the gastric mucosal PGE2 by about 98.5% compared to ethanol-induced gastric ulcer group (table 3 & fig. 3).

Effect of omeprazole and L-carnitine on gastric mucosal MPO activity:

The obtained data presented in figure 3 revealed that, a significant increase in gastric tissue MPO activity by about 125.1% compared to the normal group. While, pretreatment with either omeprazole or L-carnitine significantly reduced MPO activity by about 39.7% and 48.8% respectively as compared to the ulcer control group.

Table(3): Effect of Omeprazole and L-carnitine pretreatment on titratable acidity, peptic activity and DNA fragmentation of gastric juice in ethanol-induced gastric ulcer in male albino Wister rats:

| Groups | Titratable acidity (mEq/L) | Peptic activity (µM tyrosine/ml) | DNA fragmentation (mg/L) |
|---------------|----------------------------|----------------------------------|----------------------------|
| Normal | 77.35±4.39 | 121.3±3.43 | 0.031±0.006 |
| Ulcer control | 94.36±5.9 _a | 221.6±4.67 _a | 0.114±0.008 _a |
| Omeprazole | 79.49±3.73 ^b | 158.4±4.25 _{a,b} | 0.051±0.012 _{a,b} |
| L-carnitine | 81.56±4.83 ^b | 157.5±5.74 _{a,b} | 0.041±0.009 _b |

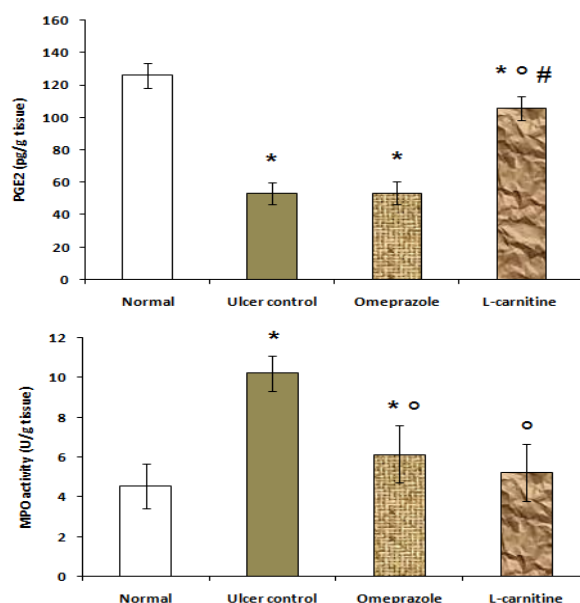


Figure (3): Effect of Omeprazole and L-carnitine pretreatment on PGE2 and MPO activity in ethanol-induced gastric ulcer in male albino Wister rats: Data are given as mean ± SD. *P < 0.05 vs normal group. °P < 0.05 vs ulcer control group. #P < 0.05 vs omeprazole group.

Effect of omeprazole and L-carnitine on titratable acidity and peptic activity of the gastric juice:

The ulcer control group showed significant increase of titratable acidity and peptic activity

compared to the normal group. In comparison with ulcer control group, both titratable acidity and peptic activity significantly decreased due to pretreatment with either omeprazole or L-carnitine respectively with no significant difference between the omeprazole treated group and L-carnitine treated group, table 3 and figure 4.

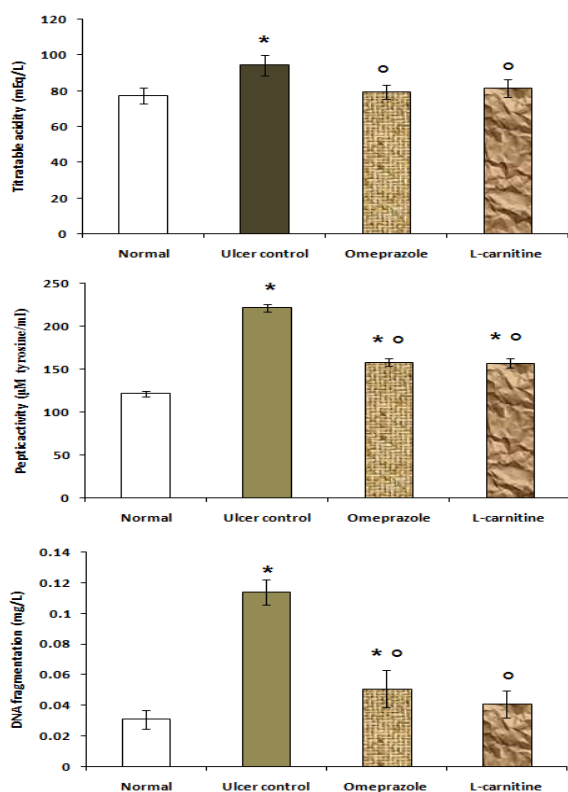


Figure (4): Effect of Omeprazole and L-carnitine pretreatment on titratable acidity, peptic activity and DNA fragmentation of gastric juice in ethanol-induced gastric ulcer in male albino Wister rats: Data are given as mean \pm SD. * $P < 0.05$ vs normal group. [°] $P < 0.05$ vs ulcer control group. [#] $P < 0.05$ vs omeprazole group.

Effect of omeprazole and L-carnitine on DNA fragmentation in gastric juice:

As shown in table 3 and figure 4, the fragmented DNA level in gastric juice was significantly increased in the ulcer control by about 267.7% compared the normal group. While, both

omeprazole and L-carnitine pretreatment significantly decreased DNA fragmentation by about 55.3% and 64% respectively compared to the ulcer control group. But, no significant difference between the omeprazole treated group and L-carnitine treated group.

DISCUSSION

Ethanol serves as a common ulcerogenic agent and when given intragastrically to rats it produces severe hemorrhagic erosions(37). Oral administration of absolute ethanol in rats is in fact noxious for the stomach, affecting the gastric mucosa topically by disrupting its barriers and provoking pronounced microvascular changes in few minutes after its application(38).

In our present study, intragastric administration of ethanol induced damage to the gastric mucosa that was evidenced by macroscopic examination that showed significant increase of ulcer index compared to the normal group. Also, ethanol caused oxidative stress manifested by significant decrease of TAC and activity of SOD in the gastric mucosa. However, the CAT activity was unchanged. These results are in line with previous reports that demonstrated marked alterations in the enzymatic antioxidants following acute administration of alcohol(37). The mechanisms of ethanol-induced gastric ulcers are not fully understood. Indeed, the genesis of the ethanol-induced gastric lesions is multifactorial, many postulates have been hypothesized(39). Depletion of non-protein sulfhydryls concentration(40), modulation of NO system regulation(41), reduction of mucosal blood flow(8) have been suggested to be involved in the development of gastric lesions, One of the major mechanisms

suggested to underlie the induction of gastric lesions by ethanol is the oxidative damage with its dual events of lipid peroxidation and oxygen reactive species (ROS) generation(42). Actually, ROS have been implicated in the pathogenesis of gastric tissue damage and ulcerogenesis(43). Ethanol also leads to increased neutrophil infiltration into the gastric mucosa(44) as it was proved in our results. These neutrophils adhere to endothelial cells, thereby blocking capillaries and induce damage to the endothelial cells through release of proteases, leukotrienes and ROS(45).

In our present study, omeprazole showed when it was given for 2 weeks (20mg/kg/day), gastroprotective effect against ethanol-induced gastric ulcer, this was proved by significant decrease of ulcer index as compared to the ulcer-control, with preventive index was 54.7%. Also, showed significant increase of TAC and SOD activity without any change in CAT activity in the gastric mucosa compared to ulcer control. Our results were in agreement with previous study demonstrated that pretreatment with omeprazole decreased gastric lesion formation(46).

The gastroprotective effect of omeprazole was suggested to be due to inhibiting gastric acid secretion(47), and also may be due to its antioxidant effect to block gastric ulcer through scavenging of endogenous hydroxyl radical associated lipid peroxidation and protein oxidation, indicating oxidative damage(48).

Administration of L-carnitine in the current study significantly decreased the gastric mucosal damage as proved by significant decrease of ulcer index compared to ethanol-induced gastric ulcer group, with preventive index was 67.6%, also our findings demonstrated that pretreatment with L-

carnitine significantly increased the TAC and SOD activity without change of the CAT activity in gastric mucosa compared to the ulcer control. These data are in harmony with the results of Shaker et al.(49). The gastroprotective effect of L-carnitine observed in the current study could possibly be mediated through its well-known antioxidant property(50). L-carnitine has the ability to scavenge H₂O₂ and hydroxyl radicals and may inhibit hydroxyl radical production(51).

The present study revealed that ethanol administration resulted in significant decreased production of gastric NO content compared to the normal control. These results were in accordance with the findings of Vera-Arzave et al.(52). This could be explained by the decrease of NO biosynthesis consequent to decreased nitric oxide synthase activity associated with increased mucosal damage(53). Endogenous NO plays an important role in the protection of gastric mucosa possibly through maintenance of mucosal blood(54).

In the present study, pretreatment with omeprazole caused insignificant change in gastric NO content compared to the ulcer control group. However, L-carnitine, 2 weeks prior to ethanol-induced gastric ulcer, significantly increased NO level in gastric mucosa as compared to ethanol alone. The increased NO level in gastric mucosa by L-carnitine could be attributed to the activation of NO synthase by phosphorylation and increased NO bioavailability(55).

In the present study, the production of both acidic mucopolysaccharides and PGE₂ in the gastric wall was significantly reduced by ethanol administration compared to the normal rats. The decrement of mucosal PGE₂ content was probably

due to endothelial dysfunction due to decrease mucosal blood flow caused by ethanol administration(56). PGE2 plays an important role in the regulation of gastric mucosal integrity(57). A reduction of PGE2 leads to decrease in mucus synthesis in the gastric wall(58).

In our present study, omeprazole pretreatment failed to prevent the decrease in PGE2 and acidic mucopolysaccharides production in the gastric wall. But, L-carnitine significantly increased both PGE2 and acidic mucopolysaccharides production compared to rats received ethanol alone. It is probable that antioxidant activity of L-carnitine kindred the injurious effect of ethanol on endothelial integrity and hence prevented the ethanol-induced reduction in PGE2 and mucus content of the gastric mucosa(21). Also, the L-carnitine-induced PGE2 production could be mediated by its influence at the level of both cyclooxygenase expression and substrate formation(59). Another possible mechanism for increased PGE2 level may be explained in part by the stimulatory effect of L-carnitine on NO production(60), as it was reported that NO increased PGE2 synthesis in vivo through cGMP-independent mechanism and it was assumed that NO might regulate the release and/or the synthesis of PGE2 in the stomach after damage(61).

The acidic mucopolysaccharides secretion is physiologically regulated by both NO and PGE2(21), and since both NO and PGE2 were significantly increased by L-carnitine, it will be expected to find a concomitant increase in mucus level with subsequent improvement in ulcerative lesions, which was confirmed in the present study.

The present study indicated that ethanol administration significantly increased MPO

activity in the gastric mucosa compared to the normal group. MPO is an essential enzyme for normal neutrophil function, released into extracellular fluid as a response to various stimulatory substances(62). MPO activity is considered as an index for evaluation of neutrophil infiltration(63). The elevated activity of MPO in the gastric mucosa indicates oxidative injury induced by ethanol involving the contribution of neutrophil accumulation(44). The increase in enzyme activity level may be associated with increase in the levels of neutrophil infiltration and H₂O₂ in the gastric damaged tissue administered with ethanol(64). Also, one mechanism in the pathogenesis of mucosal lesions provoked by ethanol may be the circulating neutrophil(65). The leukocytes might create gastric ulcerations through various mechanisms, such as the production of reactive oxygen metabolites or the release of protease and lipid mediators(66). Moreover, activated neutrophils produce many enzymes and free radicals that damage the gastric mucosa, neutrophil is considered as an aggressive factor in ulcer formation(65).

In our present study, pretreatment with either omeprazole or L-carnitine significantly inhibited the increase in MPO activity in the gastric mucosa as compared to the ulcer control. Both omeprazole and L-carnitine restored MPO activity to the normal level, suggesting that the neutrophil infiltration could be delimited by the antioxidant agents(67). These findings were in parallel with the previous data, defining the role of neutrophils in the release of ROS(68).

The results of the present work showed that intragastric administration of ethanol in rats resulted in significant concomitant increase in

titratable gastric acidity and peptic activity of gastric juice compared to the normal control. These findings seemed to be important factors for the damage induced by ethanol.

In our present study, omeprazole significantly decreased the titratable gastric acidity and peptic activity of gastric juice. The inhibitory effect of omeprazole on gastric acid may be due to inhibition of H⁺/K⁺ ATPase pump(69), in addition, to inhibition of gastric mucosal enzymes, carbonic anhydrase II and IV(70), which are located in abundance in the gastric parietal cells and in the secretory canaliculi walls(71). The inhibitory effect of omeprazole on peptic activity was suggested to be a sequence to the inhibition of gastric acid secretion(69)

The results of the present study demonstrated that L-carnitine administration significantly prevented the increase in the titratable gastric acidity with subsequent prevention of the increase in the peptic activity of the gastric juice compared to ethanol-induced ulcer group. This may be suggested to the antioxidant effect of L-carnitine(72).

Finally, our results showed that ethanol administration significantly increased the DNA fragmentation of gastric juice compared to the normal rats. while, our present data showed that the level of the fragmented DNA was significantly decreased as a result of the treatment with either omeprazole or L-carnitine as compared to the ulcer control group. ROS have been shown to damage chromosomal DNA and other cellular components, resulting in DNA degradation and protein denaturation(73). Data revealed increased of the fragmented DNA which logically resulted from the massive cellular shedding from the mucosa into

the gastric lumen, and this in turn resulted in the augmentation of the fragmented DNA in ethanol-induced ulcer group(74). Whereas, our results showed that the fragmented DNA was significantly reduced in omeprazole and L-carnitine treated groups which was suggested to be due to intact gastric mucosa. There are several previous reports utilized gastric juice fragmented DNA content as a marker for the extent of cellular death in ulceration models(74).

CONCLUSION

L-carnitine exerts its anti-ulcer activity in ethanol induced gastric ulcer rat models, not only by its antioxidant properties via increasing TAC and SOD activity in gastric mucosa, but also by increasing the production of NO, PGE2 and acidic mucopolysaccharides in gastric tissue, by antisecretory effect via decreasing gastric titratable acidity and peptic activity and finally by preventing apoptosis via decreasing DNA fragmentation. While, omeprazole exerts its anti-ulcer activity by also antioxidant, antisecretory and anti-apoptotic properties, without affecting the production of NO, PGE2 and acidic mucopolysaccharides contents in gastric wall.

So, we conclude that L-carnitine is more effective in protection against gastric ulcer than omeprazole. Therefore, we suggest that the use of L-carnitine in the therapy of gastric ulcer in routine practice. Further studies as well as clinical trials should be conducted before the use of L-carnitine as routine medicine.

Acknowledgments:

Many thanks for Dr Karima Eldesoky, the professor of pathology for her help in the

macroscopic examination of gastric mucosal lesions.

REFERENCES

- 1. Tulassay Z, Herszényi L:** Gastric mucosal defense and cytoprotection. *Best Pract Res Clin Gastroenterol.* 24 (2): 99-108, 2010.
- 2. Tack J, Talley NJ:** "Gastroduodenal disorders," *Am. J. Gastroenterol.*, 105 (4): 757–63, 2010.
- 3. Jaiswala S, Raoa C, Sharma B:** Gastroprotective effect of standardized leaf extract from *Argyreia speciosa* on experimental gastric ulcers in rats. *J. Ethnopharmacol.* 137: 341–4, 2011.
- 4. Monnig AA, Prittie JE:** A review of stress-related mucosal disease. *J Vet Emerg Crit Care (San Antonio).* 21(5):484-95, 2011.
- 5. Ibrahim AY, Shaffie NM:** Protective effect of *Solanum indicum* var. *Distichum* extract on experimentally induced gastric ulcers in rat. *Global J. Pharmacol.* 7 (3): 325-32, 2013.
- 6. Li W, Huang H, Niu X, Fan T, Mu Q, Li H:** Protective effect of tetrahydrocoptisine against ethanol-induced gastric ulcer in mice. *Toxicol Appl Pharmacol.* 272(1):21-9, 2013.
- 7. Fernandes HB, Silva FV, Passos FF, Bezerra RD, Chaves MH, Oliveira FA, Oliveira RC:** Gastroprotective effect of the ethanolic extract of *Parkia platycephala* Benth. leaves against acute gastric lesion models in rodents. *Biol Res.* 43(4):451-7, 2010.
- 8. Sowndhararajan K, Kang SC:** Protective effect of ethyl acetate fraction of *Acacia ferruginea* DC. against ethanol-induced gastric ulcer in rats. *J Ethnopharmacol.* 148 :175–81, 2013.
- 9. Haas SL, Ye W, Löhr JM:** Alcohol consumption and digestive tract cancer. *Curr Opin Clin Nutr Metab Care.* 15(5):457-67, 2012.
- 10. Scheiman JM:** The use of proton pump inhibitors in treating and preventing NSAID-induced mucosal damage. *Arthritis Res Ther.* 15 Suppl 3:S5, 2013.
- 11. Cheng HC, Sheu BS:** Intravenous proton pump inhibitors for peptic ulcer bleeding: Clinical benefits and limits. *World J Gastrointest Endosc.* 3(3): 49–56, 2011.
- 12. Illueca M, Wernersson B, Henderson C, Lundborg P:** Maintenance treatment with proton pump inhibitors for reflux esophagitis in pediatric patients: a systematic literature analysis. *J Pediatr Gastroenterol Nutr.* 51:733-40, 2010.
- 13. Savarino V, di Mario F, Scarpignato C:** Proton pump inhibitors in GORD: an overview of their pharmacology, efficacy and safety. *Pharmacol Res.* 59:135-53, 2009.
- 14. Li JL, Wang QY, Luan HY, Kang ZC, Wang CB:** Effects of L-carnitine against oxidative stress in human hepatocytes: involvement of peroxisome proliferator-activated receptor alpha. *J Biomed Sci.* 19:32, 9 pages, 2012.
- 15. Graham DY, Genta RM:** Long term protons pump inhibitor use and gastrointestinal cancer. *Curr Gastroenterol Rep.* 10(6): 543–7, 2008.
- 16. Taysi S, Okumus S, Ezirmik S, Uzun N, Yilmaz A, Akyuz M, Tekelioglu U, Dirier A, Al B:** The protective effects of L-carnitine and vitamin E in rat lenses in irradiation-induced oxidative injury. *Adv Clin Exp Med,* 1:15–21, 2011.

17. Hynes MJ, Murray SL, Andrianopoulos A, Davis MA: Role of carnitine acetyltransferases in acetyl coenzyme A metabolism in *Aspergillus nidulans*. *Eukaryot Cell*. 10(4):547-55, 2011.
18. Dayanand CD, Krishnamurthy N, Ashakiran S, Shashidhar KN: Carnitine: A novel health factor-An overview. *Int J Pharm Biomed Res*. 2(2), 79-89, 2011.
19. Rizzo AM, Berselli P, Zava S, Montorfano G, Negroni M, Corsetto P, Berra B: Endogenous antioxidants and radical scavengers. *Adv Exp Med Biol*. 698:52-67, 2010.
20. Al Batran R, Al-Bayaty F, Abdulla MA, Al-Obaidi MM, Hajrezaei M, Hassandarvish P, Fouad M, Golbabapour S, Talaei S: Gastroprotective effects of *Corchorus olitorius* leaf extract against ethanol-induced gastric mucosal hemorrhagic lesions in rats. *J Gastroenterol Hepatol* 28(8):1321-9, 2013.
21. Izgüt-Uysal VN, Bülbül M, Tan R, Derin N, Ustünel I, Açar A, Yargıçođlu P: Effect of chronic stress and L-carnitine on rat stomach. *J Physiol Sci*. 57(3):187-92, 2007.
22. Morjan S, Al Laham S, Atieh R: Gastroprotective efficacy of folic acid and omeprazole in indomethacin-induced gastropathy in rats. *International Journal of Pharmacognosy and Phytochemical Research*. 5(2): 113-9, 2013.
23. Chandra P, Sachan N, Kishore K, Ghosh AK: Acute, sub-chronic oral toxicity studies and evaluation of antiulcer activity of Sooktyn in experimental animals *J Adv Pharm Technol Res*. 3(2):117-23, 2012.
24. Kanter M, Halit D, Cengiz K, Hanefi O: Gastroprotective activity of *Nigella sativa* L oil and its constituent, thymoquinone against acute alcohol-induced gastric mucosal injury in rats. *World J. Gastroenterol*. 11, 6662-6, 2005.
25. Mukherjee M, Bhaskaran N, Srinath R, Shivaprasad H: Anti-ulcer and antioxidant activity of GutGard. *Indian J. Exp. Biol*. 48, 269-74, 2010.
26. Gregory M, Vithalrao K, Franklin G, Kalaichelavan V: Anti-ulcer (ulcer-preventive) activity of *Ficus arnottiana* Miq. (Moraceae) leaf methanolic extract. *Am. J. Pharmacol. Toxicol*. 4, 89-93. 2009.
27. Koracevic D, Koracevic G, Djordjevic V, Andrejevic S, Cosic V: Method for the measurement of antioxidant activity in human fluids. *J Clin Pathol*. 54(5):356-61, 2001.
28. Misra HP, Fridovich I: The role of superoxide anion in the autooxidation of epinephrine and a simple assay for superoxide dismutase. *J Biol Chem*. 25(247): 3170-5, 1972.
29. Aebi HE: Catalase. In: Bergmeyer HV, Bergmeyer J, Grabl M, editors. *Methods of enzymatic analysis*. Third ed. Vol: 3. Germany: VCH Verlagsgesellschaft mbH, p. 273-88, 1983.
30. Miranda KM, Espey MG, Yamada K, Krishna M, Ludwick N, Kim S, Jourdeuil D, Grisham MB, Feelisch M, Fukuto JM, Wink DA: Unique oxidative mechanisms for the reactive nitrogen oxide species, nitroxyl anion. *J Biol Chem*. 276 (3):1720-7, 2001.
31. Yusuf S, Nok AJ, Ameh DA, Adelaiye AB, Balogun EO: Quantitative changes in gastric mucosal glycoproteins: effect of cholinergic agonist and vagal nerve stimulation

- in the rat. *Neurogastroenterol Motil.* 16(5):613-9, 2004.
- 32. Shimamoto C, Nakanishi Y, Katsu K, Nakano T, Kubota T, Mori H, Nakahari T:** Prostaglandin E2 release in gastric antral mucosa of guinea-pigs: basal PGE2 release by cyclo-oxygenase 2 and ACh-stimulated PGE2 release by cyclo-oxygenase 1 *Exp Physiol.* 91(6):1015-24, 2006.
- 33. Zhao W, Zhu F, Shen W, Fu A, Zheng L, Yan Z, Zhao L, Fu G:** Protective effects of DIDS against ethanol-induced gastric mucosal injury in rats *Acta Biochim Biophys Sin (Shanghai).* 41(4):301-8, 2009.
- 34. Cylwik B, Dlugosz JW, Kemonia A, Szmikowski M:** The effect of intragastric ammonia production on titratable gastric acid output in *Helicobacter pylori*-infected patients with chronic gastritis *Dig Dis Sci.* 50(11):2094-9, 2005.
- 35. Onasanwo SA, Singh N, Olaleye SB, Mishra V, Palit G:** Anti-ulcer & antioxidant activities of *Hedranthera barteri* {(Hook F.) Pichon} with possible involvement of H⁺, K⁺ ATPase inhibitory activity *Indian J Med Res.* 132:442-9, 2010 Oct.
- 36. Kurita-Ochiai T, Fukushima K, Ochiai K:** "Lipopolysaccharide stimulates butyric acid-induced apoptosis in human peripheral blood mononuclear cells," *Infection and Immunity.* 67(1): 22-9, 1999.
- 37. Mei X, Xu D, Xu S, Zheng Y, Xu S:** Novel role of Zn(II)-curcumin in enhancing cell proliferation and adjusting proinflammatory cytokine-mediated oxidative damage of ethanol-induced acute gastric ulcers. *Chem Biol Interact.* 197(1):31-9, 2012.
- 38. Fernandes CN, De Souza HF, De Oliveria G, Costa JGM, Kerntopf MR, Campos AR:** Investigation of the mechanisms underlying the gastroprotective effect of cymbopogon citratus essential oil. *J Young Pharm.* 4(1): 28-32, 2012.
- 39. Cemek M, Yilmaz E, Buyukokuroglu ME:** Protective effect of *Matricaria chamomilla* on ethanol-induced acute gastric mucosal injury in rats. *Pharm. Biol.* 48, 757-63, 2010.
- 40. Reyes-Trejo B, Sánchez-Mendoza ME, Becerra-García AA, Cedillo-Portugal E, Castillo-Henkel C, Arrieta J:** Bioassay-guided isolation of an anti-ulcer diterpenoid from *Croton reflexifolius*: role of nitric oxide, prostaglandins and sulfhydryls. *J Pharm Pharmacol.* 60(7):931-6, 2008.
- 41. de Carvalho KI, Fernandes HB, Machado FD, Oliveira IS, Oliveira FA, Nunes PH, Lima JT, Almeida JR, Oliveira RC:** Antiulcer activity of ethanolic extract of *Encholirium spectabile* Mart. ex Schult & Schult f. (Bromeliaceae) in rodents. *Biol Res.* 43(4):459-65, 2010.
- 42. Alvarez-Suarez JM, Dekanski D, Ristic, S, Radonjic NV, Petronijevic ND, Giampieri F, Astolfi P, Gonzalez-Paramas AM, Santos-Buelga C, Tulipani S, Quiles JL, Mezzetti B, Battino M:** Strawberry polyphenols attenuate ethanol-induced gastric lesions in rats by activation of antioxidant enzymes and attenuation of MDA increase. *PLoS ONE* 6: e25878, 2011.
- 43. Gu XH, Hao Y, Wang XL:** Overexpression of heat shock protein 70 and its relationship to intestine under acute heat stress in broilers: 2.

- Intestinal oxidative stress. *Poult. Sci.* 91: 790–9, 2012.
- 44. Amaral GP, de Carvalho NR, Barcelos RP, Dobrachinski F, Portella Rde L, da Silva MH, Lugokenski TH, Dias GR, da Luz SC, Boligon AA, Athayde ML, Villetti MA, Antunes Soares FA, Fachineto R:** Protective action of ethanolic extract of *Rosmarinus officinalis* L. in gastric ulcer prevention induced by ethanol in rats. *Food Chem Toxicol.* 55: 48–55, 2013.
- 45. Segel GB, Halterman MW, Lichtman MA:** The paradox of the neutrophil's role in tissue injury. *J Leukoc Biol.* 89(3):359-72, 2011.
- 46. Kuramoto T, Umegaki E, Nouda S, Narabayashi K, Kojima Y, Yoda Y, Ishida K, Kawakami K, Abe Y, Takeuchi T, Inoue T, Murano M, Tokioka S, Higuchi K:** Preventive effect of irsogladine or omeprazole on non-steroidal anti-inflammatory drug-induced esophagitis, peptic ulcers, and small intestinal lesions in humans, a prospective randomized controlled study. *BMC Gastroenterol.* 13:85, 2013.
- 47. Tempel M, Chawla A, Messina C, Celiker MY:** Effects of omeprazole on iron absorption: preliminary study. *Turk J Haematol.* 30(3):307-10, 2013.
- 48. Simon WA, Sturm E, Hartmann HJ, Weser U:** Hydroxyl radical scavenging reactivity of proton pump inhibitors. *Biochem Pharmacol.* 71(9):1337-41, 2006.
- 49. Shaker ME, Houssen ME, Abo-Hashem EM, Ibrahim TM:** Comparison of vitamin E, L-carnitine and melatonin in ameliorating carbon tetrachloride and diabetes induced hepatic oxidative stress. *J Physiol Biochem.* 65(3):225-33, 2009.
- 50. Solarska K, Lewińska A, Karowicz-Bilińska A, Bartosz G:** The antioxidant properties of carnitine in vitro. *Cell Mol Biol Lett.* 15(1):90-7, 2010.
- 51. Augustyniak A, Skrzydlewska E:** The influence of L-carnitine supplementation on the antioxidative abilities of serum and the central nervous system of ethanol-induced rats. *Metab Brain Dis.* 25(4):381-9, 2010.
- 52. Vera-Arzave C, Antonio LC, Arrieta J, Cruz-Hernández G, Velasquez-Mendez AM, Reyes-Ramírez A, Sánchez-Mendoza ME:** Gastroprotection of suaveolol, isolated from *Hyptis suaveolens*, against ethanol-induced gastric lesions in Wistar rats: role of prostaglandins, nitric oxide and sulfhydryls. *Molecules.* 17(8): 8917-27, 2012.
- 53. Heeba GH, Hassan MK, Amin RS:** Gastroprotective effect of simvastatin against indomethacin-induced gastric ulcer in rats: role of nitric oxide and prostaglandins. *Eur. J. Pharmacol.* 607, 188–93, 2009.
- 54. Sánchez-Mendoza ME, Reyes-Ramírez A, Cruz Antonio L, Martínez Jiménez L, Rodríguez-Silverio J, Arrieta J:** Bioassay-guided isolation of an anti-ulcer compound, tagitinin C, from *Tithonia diversifolia*: role of nitric oxide, prostaglandins and sulfhydryls. *Molecules.* 16(1):665-74, 2011.
- 55. Ning WH, Zhao K:** Propionyl-L-carnitine induces eNOS activation and nitric oxide synthesis in endothelial cells via PI3 and Akt kinases. *Vascul Pharmacol.* 59(3-4):76-82, 2013.

- 56. Zhao W, Zhu F, Shen W, Fu A, Zheng L, Yan Z, Zhao L, Fu G:** Protective effects of DIDS against ethanol-induced gastric mucosal injury in rats. *Acta Biochim Biophys Sin (Shanghai)*. 41(4):301-8, 2009.
- 57. Slomiany BL, Slomiany A:** Ghrelin protection against cytotoxic effect of ethanol on rat salivary mucin synthesis involves cytosolic phospholipase A2 activation through S-Nitrosylation. *Int J Biomed Sci*. 6(1):37-44, 2010.
- 58. Ketuly KA, Hadi AH, Golbabapour S, Hajrezaie M, Hassandarvish P, Ali HM, Abdul Majid N, Abdulla MA:** Acute toxicity and gastroprotection studies with a newly synthesized steroid. *PLoS One*. 8(3):e59296, 2013.
- 59. Alves E, Binienda Z, Carvalho F, Alves CJ, Fernandes E, de Lourdes Bastos M, Tavares MA, Summavielle T:** Acetyl-L-carnitine provides effective in vivo neuroprotection over 3,4-methylenedioxymethamphetamine-induced mitochondrial neurotoxicity in the adolescent rat brain. *Neuroscience*. 158(2):514-23, 2009.
- 60. Mingorance C, Duluc L, Chalopin M, Simard G, Ducluzeau PH, Herrera MD, Alvarez de Sotomayor M, Andriantsitohaina R:** Propionyl-L-carnitine corrects metabolic and cardiovascular alterations in diet-induced obese mice and improves liver respiratory chain activity. *PLoS One*. 7(3):e34268, 2012.
- 61. Salvemini D, Kim SF, Mollace V:** Reciprocal regulation of the nitric oxide and cyclooxygenase pathway in patho-physiology: relevance and clinical implications. *Am J Physiol Regul Integr Comp Physiol*. 304:R473-87, 2013.
- 62. Ozbakiş-Dengiz G, Cadırcı E, Yurdakan G:** Histopathologic evaluation of anti-ulcerogenic effect of montelukast in indomethacin-induced experimental ulcer model. *Turk J Gastroenterol*. 24(2):88-92, 2013.
- 63. Esposito G, Capoccia E, Sarnelli G, Scuderi C, Cirillo C, Cuomo R, Steardo L:** The antiprotozoal drug pentamidine ameliorates experimentally induced acute colitis in mice. *J Neuroinflammation*. 9:277, 2012.
- 64. Li NS, Luo XJ, Zhang YS, He L, Liu YZ, Peng J:** Phloroglucinol protects gastric mucosa against ethanol-induced injury through regulating myeloperoxidase and catalase activities. *Fundam Clin Pharmacol*. 25(4):462-8, 2011.
- 65. Aysun T, Fatih A, Hülya A, Halis S, Ufuk Ö, Havva E:** The effects of acetyl shikonin isolated from *Onosma armeniacum* on oxidative stress in ethanol-induced ulcer model of rats. *Turk J Med Sci*. 43: 315-20, 2013.
- 66. Megala J, Geetha A:** Gastro protective and antioxidant effects of hydro alcoholic fruit extract of *pithecellobium dulce* on ethanol induced gastric ulcer in rats. *Pharmacologyonline*, 2: 353-72, 2010.
- 67. Zygmunt M, Dudek M, Bilska-Wilkosz A, Bednarski M, Mogilski S, Knutelska J, Sapa J:** Anti-inflammatory activity of lipoic acid in mice peritonitis model. *Acta Pol Pharm*. 70(5):899-904, 2013.
- 68. Guerra BA, Bolin AP, Morandi AC, Otton R:** Glycolaldehyde impairs neutrophil biochemical parameters by an oxidative and calcium-dependent mechanism-

protective role of antioxidants astaxanthin and vitamin C. *Diabetes Res Clin Pract.* 98(1):108-18, 2012.

69. Ito T, Jensen RT: Association of long-term proton pump inhibitor therapy with bone fractures and effects on absorption of calcium, vitamin B12, iron, and magnesium. *Curr Gastroenterol Rep.* 12(6):448-57, 2010.

70. Thippeswamy A. H. M., Sajjan M., Palkar M. B., Koti B. C., Viswanathaswamy A. H. M.: Comparative study of proton pump inhibitors on dexamethasone plus pylorus ligation induced ulcer model in rats. *Indian J Pharm Sci.* 72(3): 367-71, 2010.

71. Barone S, Amlal H, Xu J, Soleimani M: Deletion of the Cl-/HCO₃- exchanger pendrin downregulates calcium-absorbing proteins in

the kidney and causes calcium wasting. *Nephrol Dial Transplant.* 27(4): 1368-79, 2012.

72. Erkin B, Dokmeci D, Altaner S, Turan FN: Gastroprotective effect of L-carnitine on indomethacin-induced gastric mucosal injury in rats: a preliminary study. *Folia Med (Plovdiv).* 48(3-4):86-9, 2006.

73. Kryston TB, Georgiev AB, Pissis P, Georgakilas AG: Role of oxidative stress and DNA damage in human carcinogenesis. *Mutat Res.* 711(1-2):193-201, 2011.

74. Tuorkey MJ, Abdul-Aziz KK: A pioneer study on the anti-ulcer activities of copper nicotinate complex [CuCl (HNA)₂] in experimental gastric ulcer induced by aspirin-pylorus [corrected] ligation model (Shay model). *Biomed Pharmacother.* 63(3):194-201, 2009.

فى ذكور الفئران الببضاء من النوع وستر

نرمين محمد ماضى* , أنعام صلاح عبد البير**

أقسام الفسيولوجيا* والكليكال باثولوجى**

كلية الطب، جامعة طنطا

هدف البحث: يهدف هذا البحث الى دراسة لمقارنة التأثير الوقائى لل- كارنتين والأومبيرازول على قرحة المعدة المستحثة بالايثانول فى ذكور الفئران الببضاء من النوع وستر. **طرق البحث:** أجريت هذه الدراسة على 40 من الفئران الألبينو وتم تقسيمها الى أربع مجموعات وهى كالاتى: المجموعة الطبيعية التى يتم إعطائها ماء مقطر -المجموعة الضابطة للقرحة والتى يتم إعطائها جرعة واحدة من الايثانول بجرعة واحد مل لاحداث القرحة- مجموعة الأومبيرازول و يتم اعطائها أومبيرازول بجرعة 20 مجم/كجم تحت الجلد ومجموعة ل-كارنتين و يتم إعطائها ل-كارنتين بجرعة 50 مجم /كجم عن طريق الفم يوميا. وفى نهاية التجربة تم ذبح الفئران وقياس مؤشر القرحة ومؤشر الوقائية وتم أيضا إعداد مستخلص من المعدة لقياس السعة الكلية لمضادات الأكسدة ونشاط كل من السوبر أكسيد ديسميوتيز والكاتاليز, أكسيد النيتريك والميوكوبوليسكريد والبروستاجلندين E2, نشاط الميلوبيروكسيداز (MPO) وتم تجميع العصارة المعدية لقياس الحموضة, نشاط البيبينين ونواتج تكسير DNA. **النتائج:** قد أدى التلف المعدي المستحث بالايثانول الى زيادة مؤشر القرحة ونشاط الميلوبروكسيداز فى غشاء المعدة زيادة ذات دلالة إحصائية وأيضا زيادة الحموضة والنشاط البيبتيدي و نواتج تكسير DNA فى العصارة المعدية ونقص ذو دلالة إحصائية فى كل من السعة الكلية لمضادات الأكسدة ونشاط السوبر أكسيد ديسميوتيز, مستوى أكسيد النيتريك والميوكوبوليسكريد والبروستاجلندين E2 فى غشاء المعدة مع عدم تأثير يذكر فى نشاط الكاتاليز إذا قورنت بالمجموعة الطبيعية. وقد أدت المعالجة المسبقة بل-كارنتين والأومبيرازول إلى نقص ذو دلالة إحصائية فى معامل القرحة ونشاط الميلوبروكسيداز ونقص فى الحموضة والنشاط البيبتيدي ونواتج تكسير DNA فى العصارة المعدية إذا قورن بالمجموعة الضابطة للقرحة. وقد تمكن ل-كارنتين فقط وليس الأومبيرازول من زيادة كل من السعة الكلية لمضادات الأكسدة ونشاط السوبر أكسيد ديسميوتيز ومستوى أكسيد النيتريك والميوكوبوليسكريد والبروستاجلندين E2 فى غشاء المعدة وكانت الزيادة ذات دلالة إحصائية إذا قورنت بالمجموعة الضابطة للقرحة. **الخلاصة:** نستخلص مما سبق أن ل-كارنتين أكثر كفاءة من الأومبيرازول فى معالجة قرحة المعدة مما يجعلنا نوصى بالمزيد من الأبحاث والتجارب الاكلينيكية قبل استخدام ل-كارنتين كعلاج معتمد للقرحة.